

# Clinical Application and Usefulness of XI VOCAL in Volume Measurement

Hye-Sung Won, M.D.\*, Soo-Jung Lee, M.D.\*, Sun-Mee Jun, RDMS\*\*

\*Department of Obstetrics and Gynecology, University of Ulsan College of Medicine, Asan Medical Center, Seoul, Korea \*\*Samsung Medison Co., Ltd, Seoul, Korea

## INTRODUCTION & OBJECTIVE

The volume measurement of the fetal organ has been evolved with 3D ultrasound technology. The conventional method for volume measurement (VOCAL) is processed by computerizing volume data automatically from sectional diagram which is turned on a pivot. This method (VOCAL) is powerful to measure the volume of organs, especially when its shape is symmetry or globular. In spite of tremendous benefits of conventional measuring method (VOCAL), it has sometimes provided with fallible volume data in case of irregular or asymmetric lesion.

In addition, the VOCAL is required the sophisticated operation skills to users.

Unlike the VOCAL, the XI VOCAL™ (eXtended Imaging VOCAL) virtualizes actual organs with accuracy by analyzing the volume of the organs which is drawn out from sliced sectional diagram.

The purposes of this work is not only to compare the VOCAL with XI VOCAL in the measurement of the volume, especially in the irregular shaped organ, but also to assess operator's dependency.

## METHODS

### 1. EXPERIMENTAL STUDY

We used two irregular shaped phantoms known the real volume. Through 10 times measurement of the volume (VOCAL & XI VOCAL), we evaluated the accuracy of the two methods.

### 2. CLINICAL STUDY

Two cases of measuring a serial prenatal were performed. The first case was 'congenital hypothyroidism', and the second was 'unilateral pleural effusion'.

We applied for two different methods (VOCAL and XI VOCAL) for volume measurement. The Accuvix XQ (Samsung Medison Co.,Ltd, Korea) was used for this case studies.

Two operators measured same object independently using two different technologies, namely VOCAL and XI VOCAL. Each operator measured the object ten times.

# RESULTS

## 1. EXPERIMENTAL STUDY

Table 1. The values of phantom volume

Data presents Mean±SD

	Real volume(cm <sup>3</sup> )	VOCAL(cm <sup>3</sup> ): 15' rotation	VOCAL XI(cm <sup>3</sup> ): slice interval-2mm
Phantom A	4.0	4.62±0.21	3.93±0.13
Phantom B	5.9	6.5±0.1	5.94±0.15

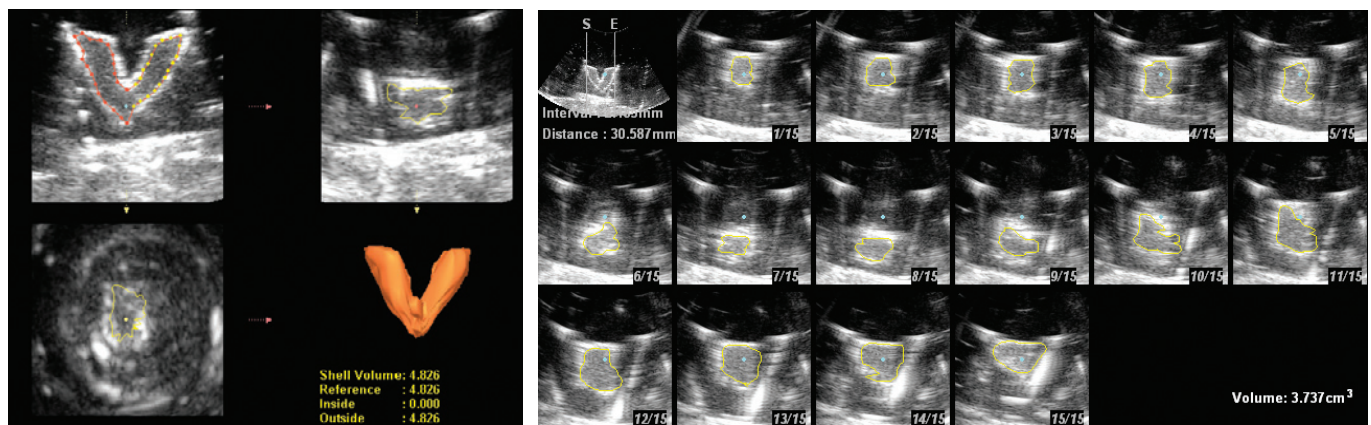


FIGURE 1: Result image of phantom A

Left: VOCAL method

Right: XI VOCAL method(slice interval was 2mm)

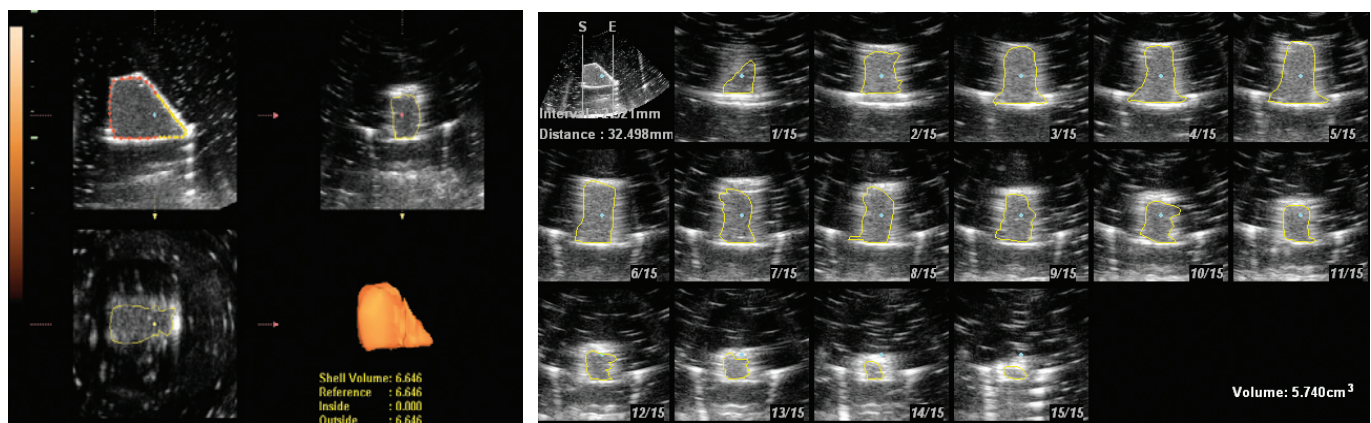




FIGURE 2: Result image of phantom B

Left: VOCAL method

Right: XI VOCAL method(slice interval was 2mm)



**2. CLINICAL STUDY**

**CASE 1 : 'Congenital hypothyroidism'**

We diagnosed the fetus which has congenital hypothyroidism at 21 weeks of gestation. We obtained the serial volume of thyroid before and after fetal therapy.

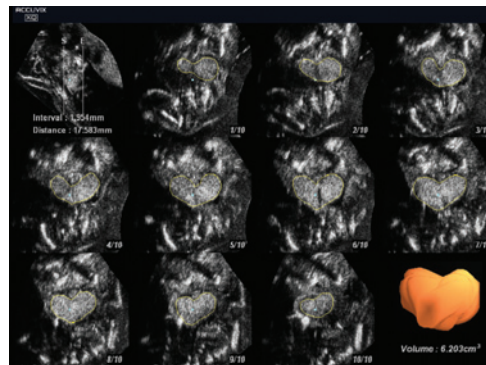
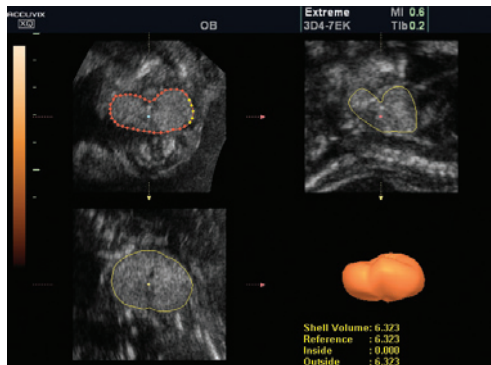
We treated the fetus with intraamniotic injection of thyroxin(200µg) at 23, 24, and 25 weeks of gestation respectively.

*Table 2. The value of thyroid volume*

	21wks	28wks
VOCAL(cm <sup>3</sup> )	6.00±0.25	4.56±0.15
XI VOCAL(cm <sup>3</sup> )	6.27±0.06	4.14±0.16

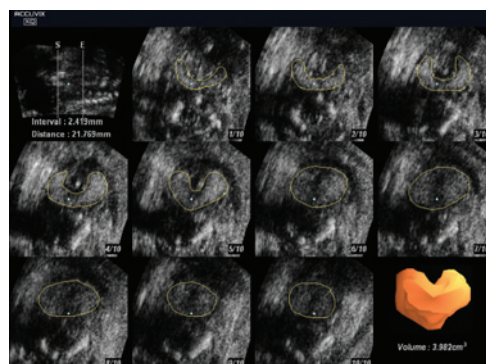
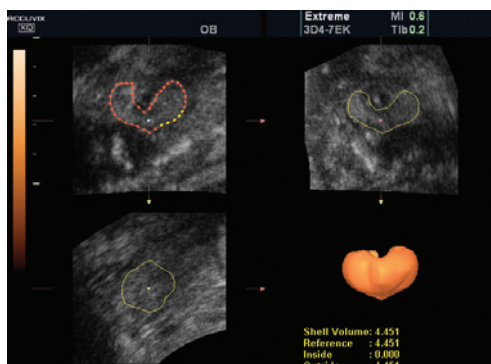Data presents Mean ±SD

P<0.05 by Fisher's exact test



**FIGURE 3:**  
Congenital hypothyroidism

Left: VOCAL method  
Right: XI VOCAL method  
- slice interval was 2mm



**FIGURE 4:**  
Follow-up scan after fetal treatment

Left: VOCAL method  
Right: XI VOCAL method  
- slice interval was 2mm

**CASE 2 : 'Unilateral pleural effusion'**

We diagnosed the fetus with unilateral(left) massive pleural effusion at 20 weeks of gestation.

We performed the thoraco-amniotic shunt operation at 21 weeks.

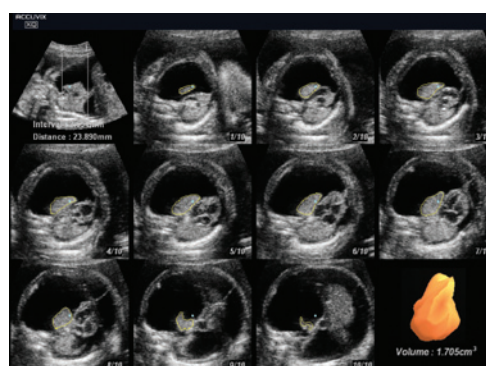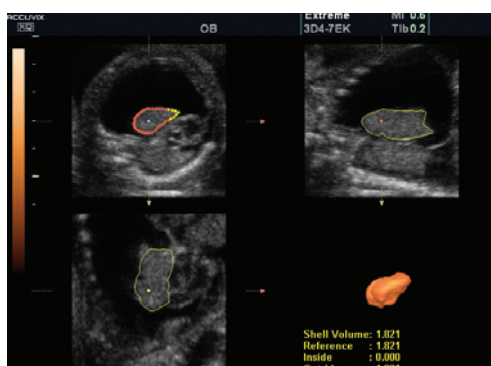We obtained the serial volume of lung before and after fetal therapy.

*Table 3. The value of lung volume*

	20 wks		31 wks	
	Rt	Lt	Rt	Lt
VOCAL(cm <sup>3</sup> )	2.94±0.12	1.96±0.11	14.36±0.69	5.39±0.22
XI VOCAL(cm <sup>3</sup> )	2.69±0.07	1.77±0.08	12.54±0.27	5.09±0.07

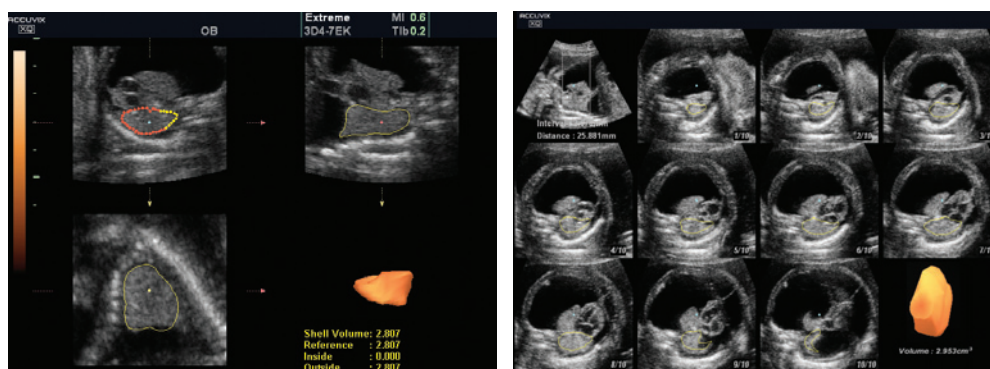
Data presents Mean ±SD

P<0.05 by Fisher's exact test

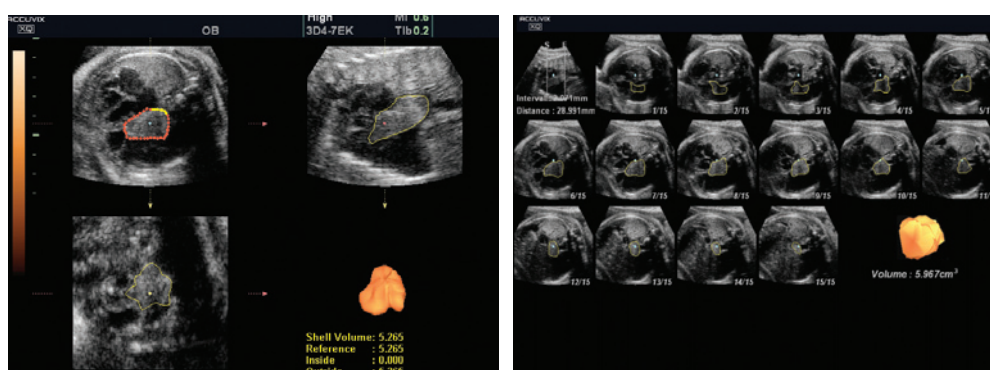


**FIGURE 5:**  
Left massive pleural effusion ;  
measuring of left lung volume

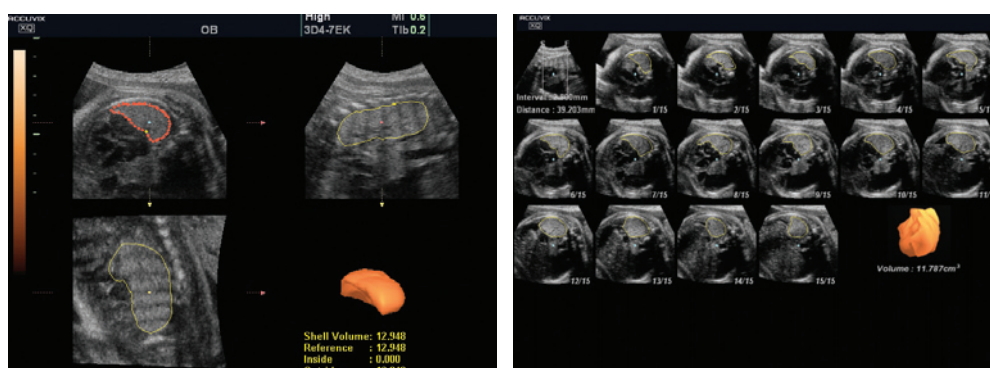
Left: VOCAL method  
Right: XI VOCAL method  
- slice interval was 2mm



**FIGURE 6:**  
 Left massive pleural effusion;  
 measuring of right lung volume  
*Left: VOCAL method*  
*Right: XI VOCAL method*  
 - slice interval was 2mm



**FIGURE 7:**  
 Follow up scan after thoraco-amniotic  
 shunt operation; measuring of left  
 lung volume  
*Left: VOCAL method*  
*Right: XI VOCAL method*  
 - slice interval was 2mm



**FIGURE 8:**  
 Follow up scan after thoraco-amniotic  
 shunt operation; measuring of right  
 volume  
*Left: VOCAL method*  
*Right: XI VOCAL method*  
 - slice interval was 2mm

## CONCLUSIONS

We demonstrated the XI VOCAL method was superior than VOCAL method to estimate volume of irregular shaped organ by experimental study. In clinical study, the difference of values of volume between two method groups were significant. With this reason, we recommend the XI VOCAL method for volume measuring of irregular shaped organ. Furthermore, we also drew conclusion that the XI VOCAL is easier method than the conventional measurement tool (VOCAL) in the view of operator's experiences.